



**PATIENT**

Cleo Hattan

**SPECIES**

Canine

**BREED**

Golden Retriever

**SEX**

Female Spayed

**AGE**

5 years

**WEIGHT**

66.3lbs

**INTERPRETED BY**

Maggie Machen  
Lamy, DVM  
DACVIM (Cardiology)

**IMAGING PERFORMED BY**

Pamela Harrigan,  
RDMS

**HOSPITAL NAME**

Foster Veterinary  
Clinic

**REFERRING VET**

Dr. Hattan

**INVOICE**

25773

**DATE**

8/15/22

**PRESENTING CLINICAL SIGNS**

History: Recheck echo. History mildly depressed LV systolic function; asymptomatic. Z/D diet. Pro BNP 1,674. BP: 119, 122, 129 mmHg. \*Sedated with gabapentin/trazadone.  
-Pertinent previous echo findings: LA 2.6 cm; LA:Ao 1.1; LV 4.3; normal LA size; borderline increased LVES dimension; mildly decreased FS (25%).

**ECHOCARDIOGRAM FINDINGS**

2D, m-mode, color flow and Doppler imaging is available.

**Left ventricle:** The LV diameter is normal in diastole with a borderline increased end-systolic dimension. The FS is mildly decreased (25%). LV wall thicknesses are normal.

**Left atrium:** The left atrium is normal.

**Mitral valve:** The mitral valve is mildly thickened with no prolapse into the left atrial lumen. Trivial central mitral regurgitation.

**Aortic valve/Aorta:** The aortic valve is normal in morphology and mobility. Normal aortic outflow velocity; laminar flow. No aortic insufficiency.

**Right ventricle:** Right ventricular is normal; no overt evidence of pulmonary arterial hypertension.

**Right atrium:** RA is normal.

**Tricuspid valve:** The tricuspid valve appears mildly thickened with no tricuspid regurgitation.

**Pulmonic valve/Pulmonary artery:** The pulmonic valve is normal in morphology and mobility. No pulmonic insufficiency. Normal RVOT velocity; laminar flow.

**Pericardium/other:** No pericardial or pleural effusion noted. No obvious cardiac masses.

**Heart rhythm:** ECG reveals a sinus rhythm with an average HR of 90bpm.

**2-Dimensional Measurements**

Ao diam (cm)	2.5
LA diam (cm)	2.7
LA:Ao (Swe)	1.2
IVS thickness (cm)	1.0
LVID diastole (cm)	4.0
PW thickness (cm)	1.0
LVID systole (cm)	3.0
FS (%)	25

**Doppler Measurements**

PV Vmax (m/s)	1.0
AoV Vmax (m/s)	1.1
MR Vmax (m/s)	NA
TR Vmax (m/s)	NA
TR PG (mmHg)	NA

**INTERPRETATION OF THE FINDINGS**

Persistently stable disease. No progression in left heart dimensions is noted, and systolic dysfunction is unchanged. No additional issues are identified.

Prognosis is open pending progression in the future.

**RECOMMENDATIONS**

- In an asymptomatic dog without significant left atrial enlargement, no cardiac medications are clearly indicated.
- Continue taurine as previously recommended.
- Anesthetic risk is considered mild if needed. Cardiac protective drug choices (opioid/benzodiazepine premedication, propofol or alfaxalone induction, isoflurane gas) are recommended. Pre-oxygenate for 5-10 minutes prior to induction. Monitor



**PATIENT**

Cleo Hattan

for arrhythmias, hypotension, and hypoxia both intra and post-operatively and intervene as necessary. Mild IV fluid restriction is recommended to avoid fluid overload. Avoid heart rate stimulating drugs such as atropine unless clinically indicated.

**SPECIES**

Canine

- Monitor for development of a cough, labored breathing, exercise intolerance or collapse episodes.

**BREED**

Golden Retriever

**PLAN**

- Recommend conservative monitoring with a recheck echocardiogram in 12 months, sooner if any development of clinical signs.

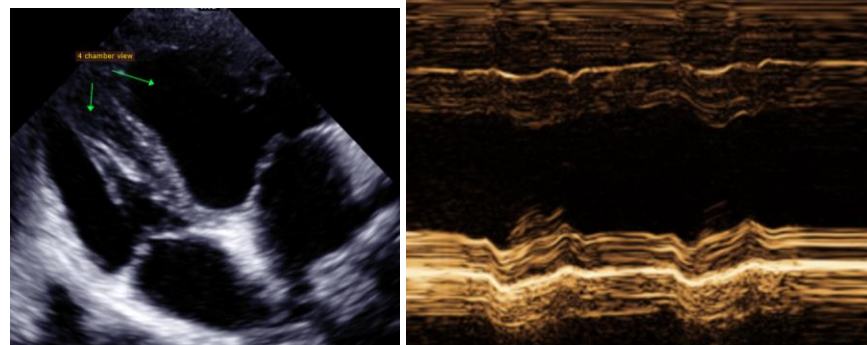
**SEX**

Female Spayed

**IMAGES**

**AGE**

5 years



**WEIGHT**

66.3lbs

**INTERPRETED BY**

Maggie Machen  
 Lamy, DVM  
 DACVIM (Cardiology)

The information and recommendations provided are based on the images presented by the referring veterinarian. No evaluation can be communicated regarding pathology that was not visible in the image/video clips provided.

**IMAGING PERFORMED BY**

Pamela Harrigan,  
 RDCS

Thank you for this referral. This report was generated using transcription software, and minor dictation errors may be present. If the clinical or image interpretation does not parallel your findings or if I can be of any further assistance, please contact me.

**Maggie Machen Lamy, DVM**  
 Diplomate of the American College of Veterinary Internal Medicine (Cardiology)  
 info@sonopath.com

**HOSPITAL NAME**

Foster Veterinary  
 Clinic

**REFERRING VET**

Dr. Hattan

**INVOICE**

25773

**DATE**

8/15/22